

The relation between epithelial and stromal area is important for colorectal cancer diagnosis and therapeutic considerations

Rogojanu R^{1,2}, Mesteri I¹, Ellinger I¹, Thalhammer T¹, Heindl A^{1,3}, Seewald A³, Häisan A⁴, Bises G¹

1) Medical University Vienna, Austria, 2) TissueGnostics GmbH, 3) Seewald Solutions, 4) Medical University of Iasi, Romania

Introduction

Colorectal cancer (CRC) is the second most frequent cause of cancer related mortality in the Western World. 35-55% of CRC operated patients develop hepatic metastases. Therefore, identifying markers for patients being at high risk for progression would be helpful for diagnosis and treatment.

Increasing evidence supports the role of the tumor microenvironment (i.e. stroma containing fibroblasts, macrophages, new vessels etc.) in influencing tumor progression, invasion and metastasis. Semi-quantitative analysis of epithelium-to-stroma ratios in microscopic sections of tumors was found to provide important information for the diagnosis and prognosis of CRC and other cancers (1, 2).

However, these studies were done by visual evaluation of cells and tissue areas, a time consuming and tedious task.

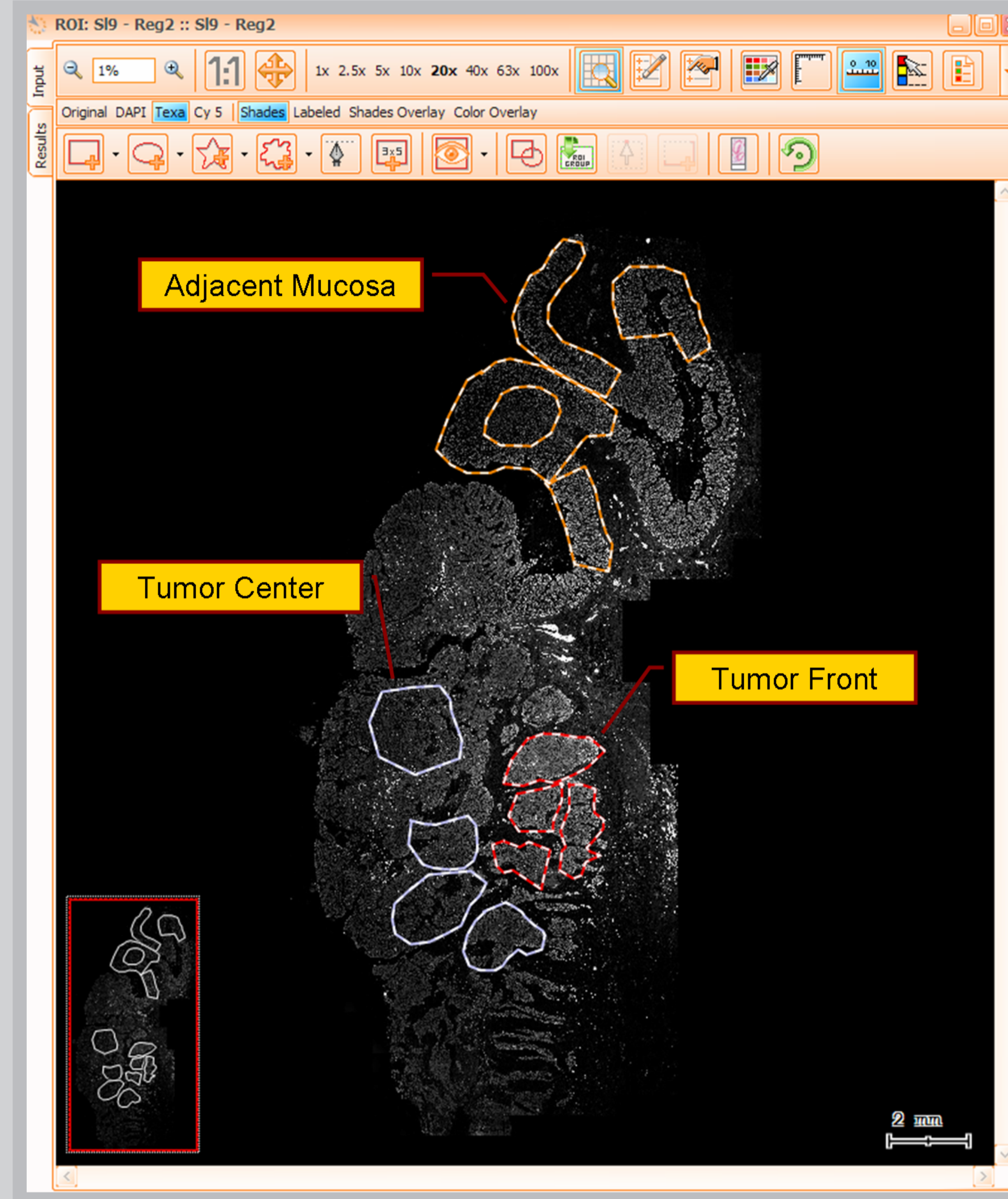


Figure 1 Different regions of interest marked up on a stitched image (keratin-8) from a colon section

Aims

Based on imaging technologies that can scan tumor sections on whole microscopic slides into virtual slides with high resolution (Fig. 1), our work aims to create algorithms that enable automated detection and measurement of the epithelial-to-stroma ratio in CRC specimens from patients.

Such algorithms will speed up measurements of tissue sections allowing for an increase of both the number of patients as well as the measured area per section thereby providing data which is more relevant from a statistical point of view.

As our algorithms work on immunofluorescence-labeled microscopic images, further analysis of epithelial- or stroma-associated parameters (e.g. localization of macrophages in relation to epithelial cells or vessels) is possible.

Results

1. Algorithm workflow

For proper detection of the epithelial area, image processing methods were established to exploit the gradient signal from the epithelial channel (Keratin-8, Fig.3) followed by adaptive normalization techniques which allow proper detection in both strong and weak areas/sections. Subsequently, algorithms were made to compute the lumen by searching for regions with low variations in a virtual channel combining information from all available fluorescence channels (Fig. 2).

The stromal area was then calculated by subtracting the epithelial and lumen areas from the total area (Fig 4.)

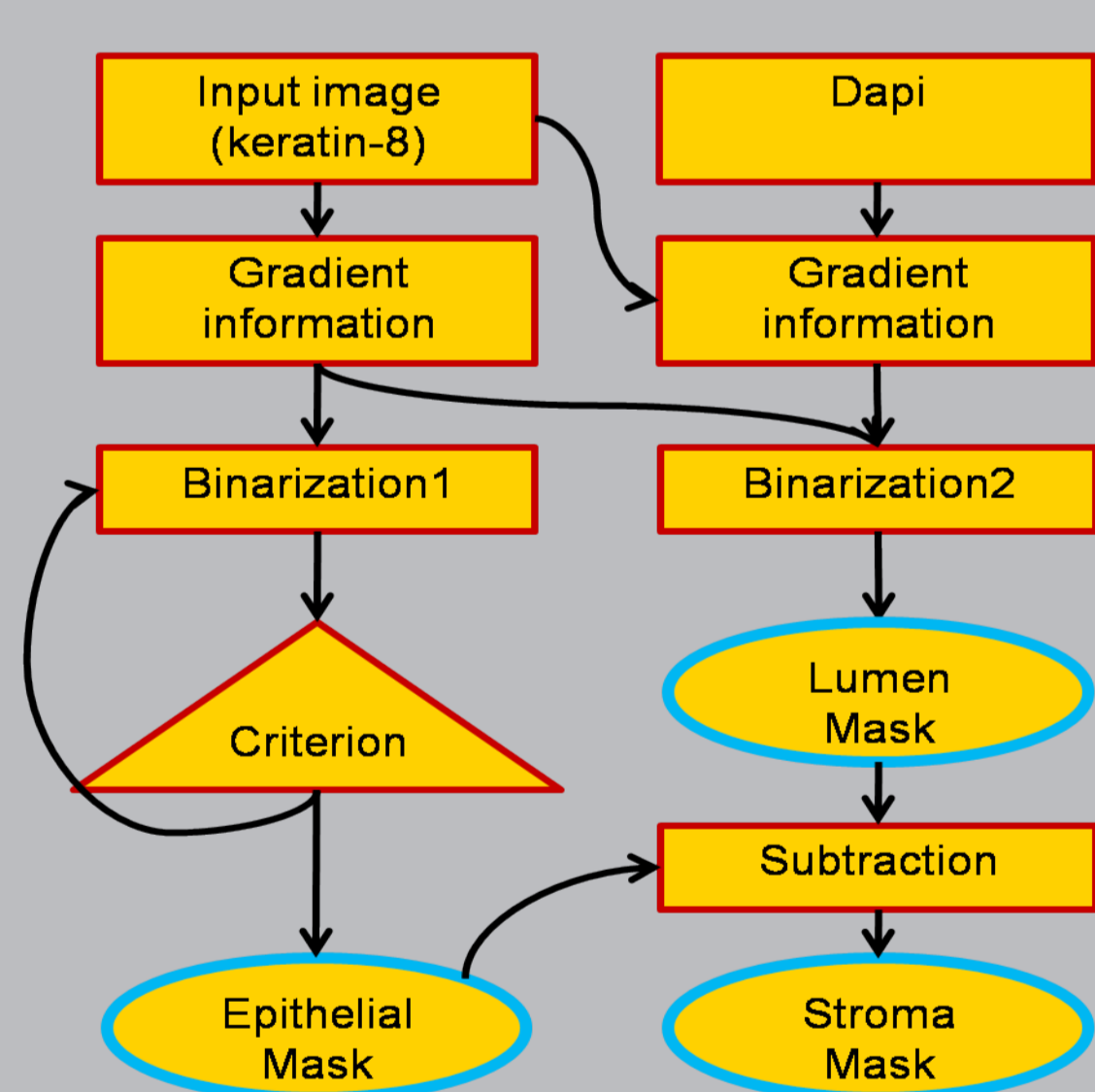


Figure 2 Algorithm workflow

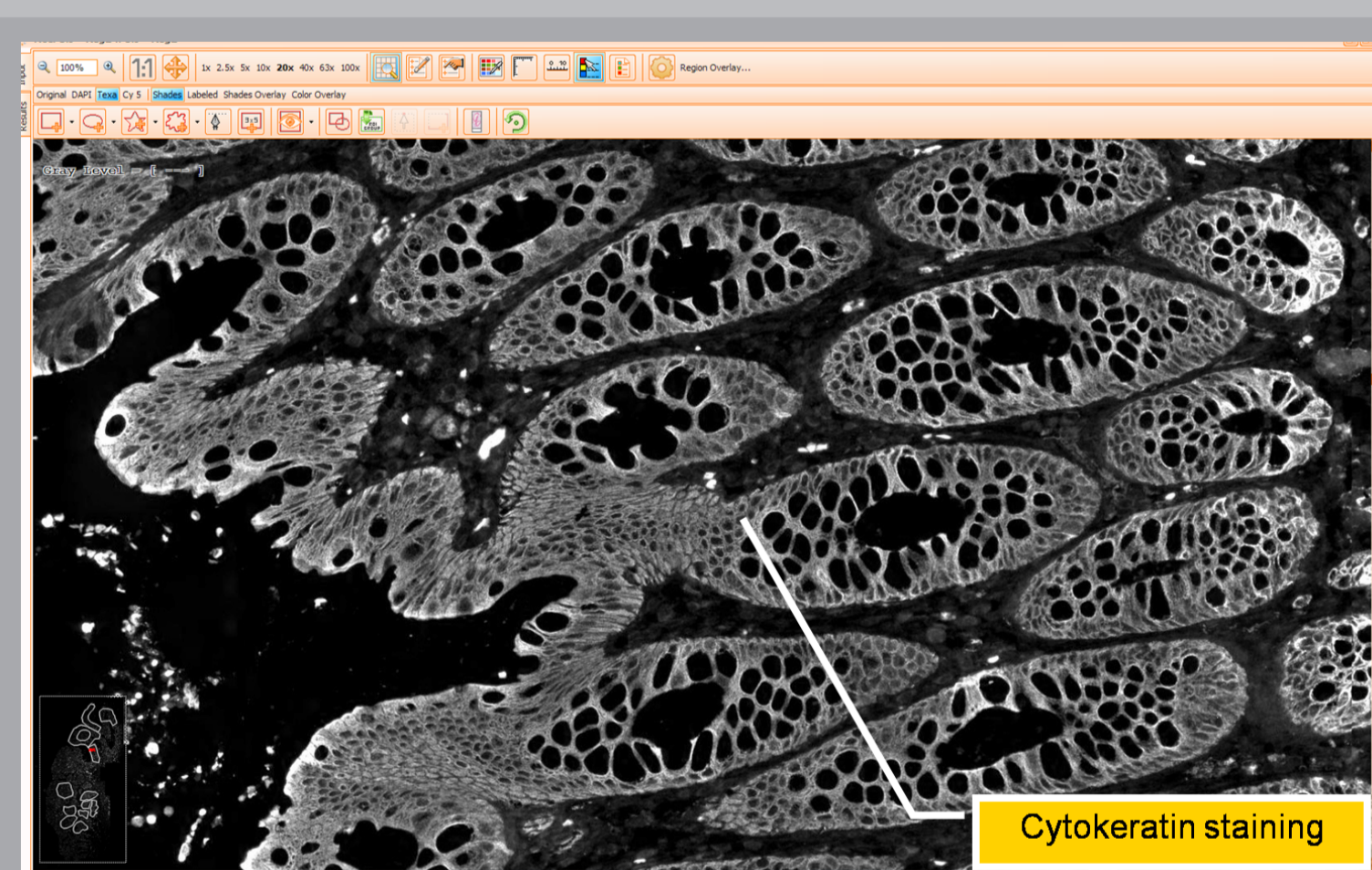


Figure 3 Grayscale original image showing epithelial cells stained with Keratin-8

2. Epithelium vs. stroma ratio in tumor areas and normal mucosa

In each scanned section from the patients with tumor, different regions of interest were manually created (Fig.1) and added in one of the corresponding group: Adjacent Mucosa (AdjMu), Tumor Front (TuF), Tumor Center (TuC).

Normal Mucosa (NM) was stained and scanned in extra slides. Measurements of epithelial-vs-stromal area ratio (E/St) of AdjMu in cancerous samples and NM were similar (ca 1:1). In the cancerous parts, as expected, the TuC showed an increased in E/St ratio of up to 3:1, due to uncontrolled growth of epithelial cells typical for carcinomas (Fig.5). However, comparing the group without liver metastasis (noLM) with the group of patients with liver metastasis (LM), we noticed a decrease of E/St ratio of 14% to 37% in all regions (AdjMu, TuF, TuC) in LM group (Fig.6).

This result is in accordance with several studies done in carcinomas, where the increase in stroma in less differentiated tumor is caused by epithelial-mesenchymal transition leading to cell migration as an onset of metastasis.

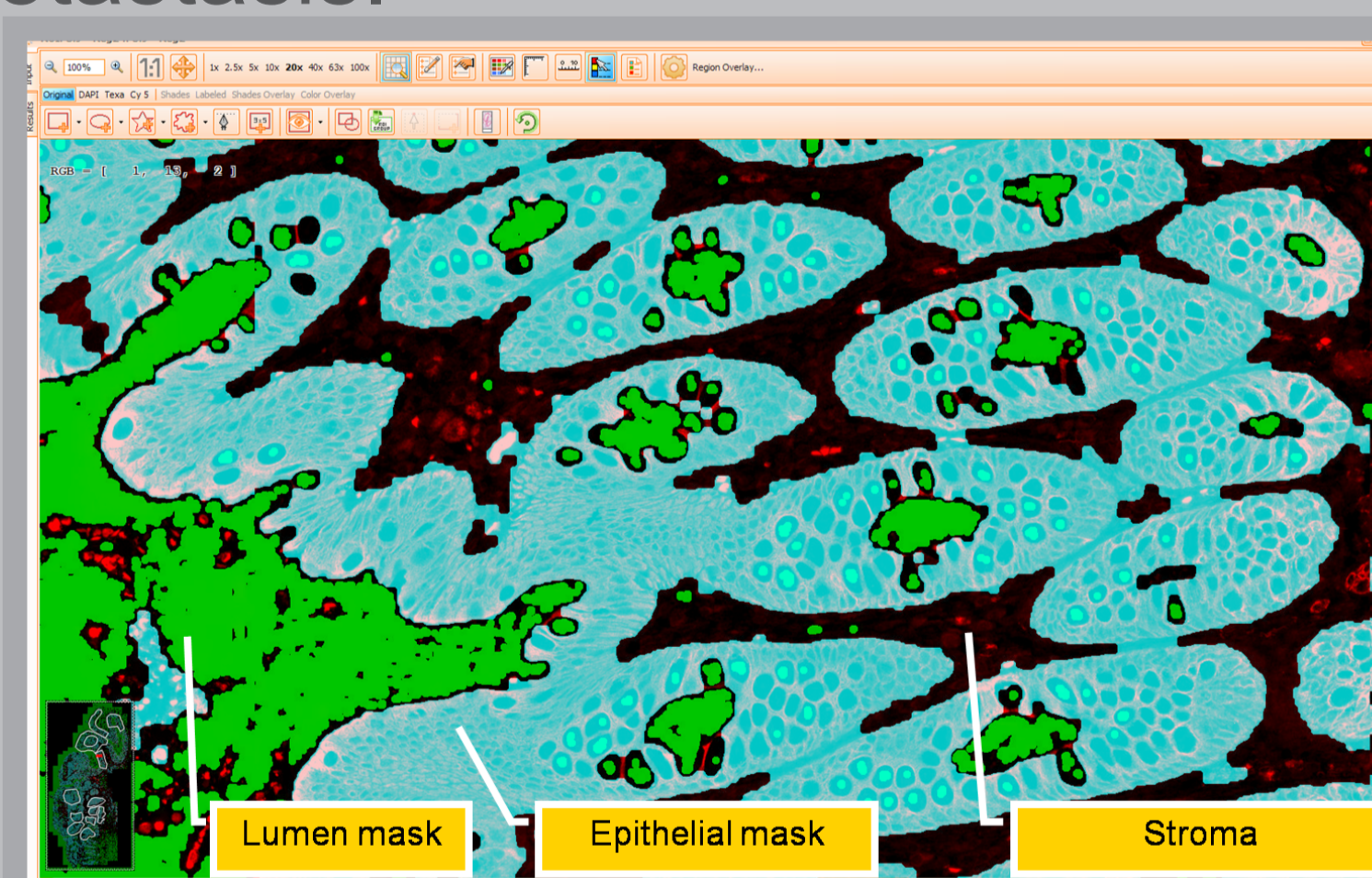


Figure 4 Resulting mask for epithelial, lumen and stroma area in a tissue section from a normal colon

Conclusion

The developed software can be used to assess the areas of epithelium and stroma and their ratios in large sample number. The information provided by these measurements can help to analyze the stroma components (fibroblasts, endothelial and inflammatory cells) in different tumor areas. This will allow a better understanding of epithelium-stroma interactions in cancer tissue, as well as to confirm the existing qualitative knowledge with new quantitative measurements.

The analysis of immunofluorescence staining based on the new algorithm permits an accurate study with special care of minor details related with specific tissue areas.

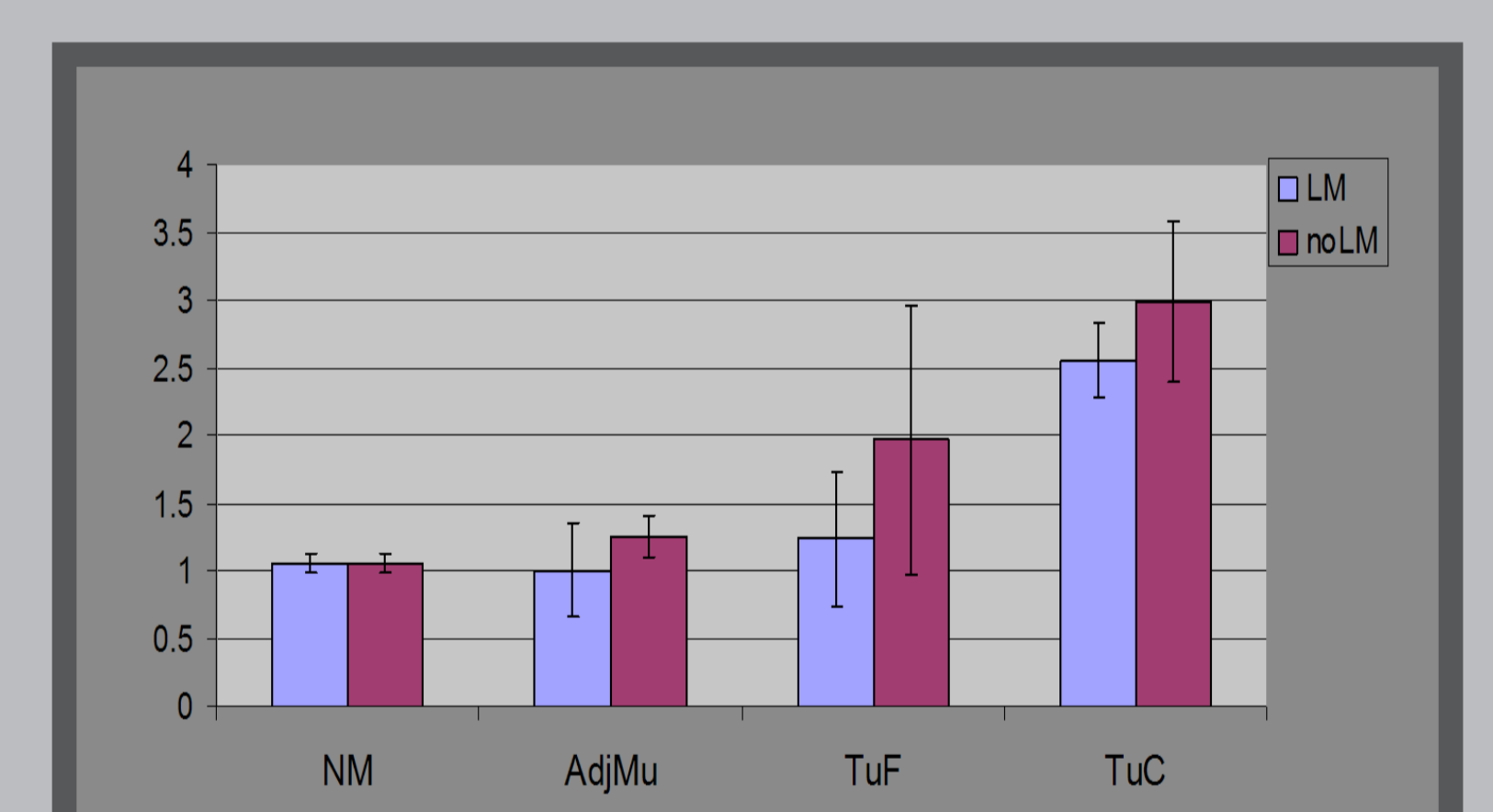


Figure 5 Epithelial vs stroma ratios in Normal Mucosa (NM), Adjacent Mucosa (AdjMu), Tumor Front (TuF) and Tumor Center (TuC) for the 2 groups

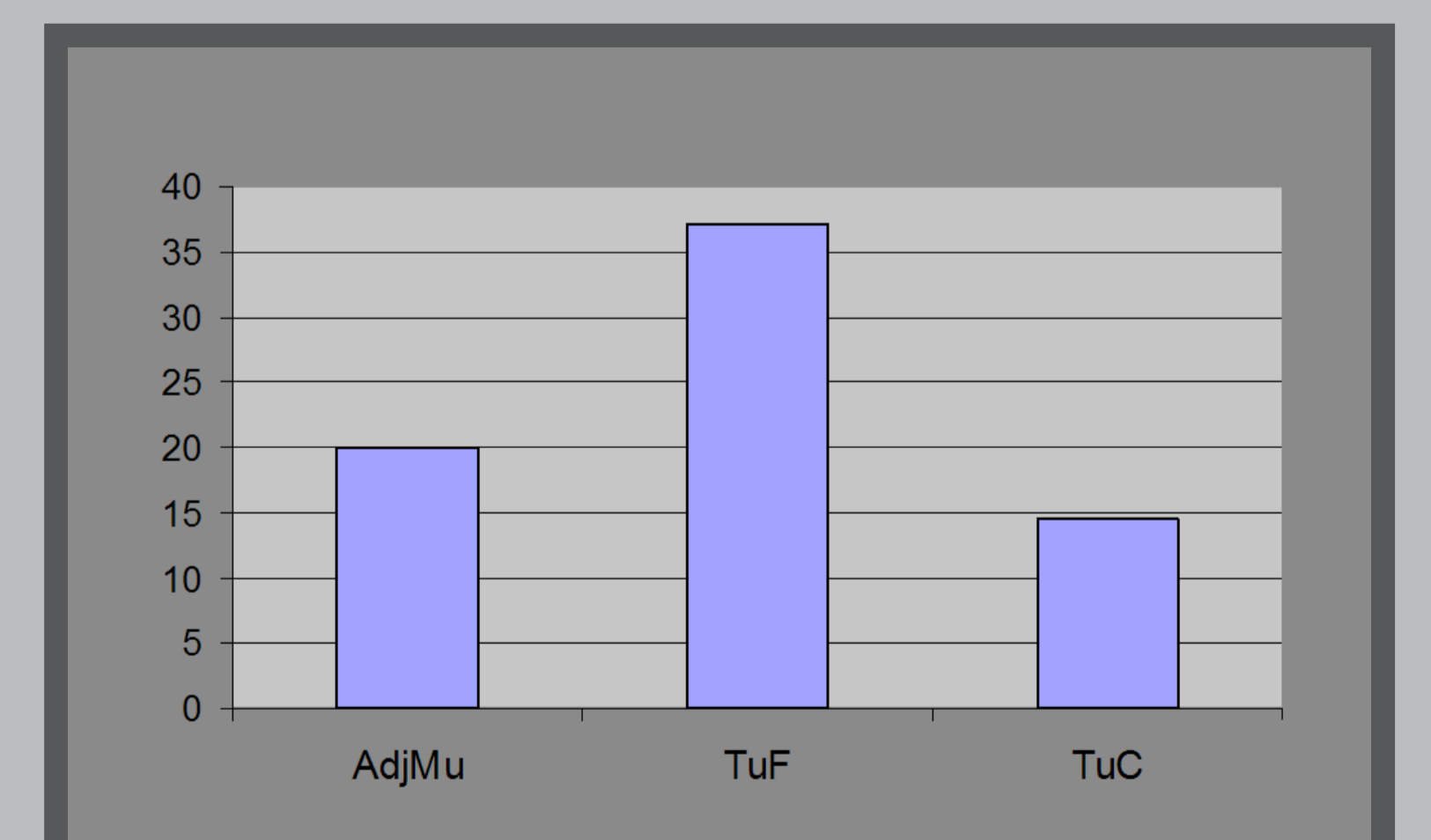


Figure 6 Decrease of E/St ratio (in %) in case of patients with LM compared with patients without LM

Methods

Immunofluorescence staining was performed in paraffin embedded sections from colorectal tumors. Epithelial cells were identified by an anti-keratin 8 antibody and a fluorochrome-labelled secondary antibody. Large areas of tissue including tumor front, tumor center as well as non cancerous mucosa adjacent to tumor tissue were

scanned using an automated microscopy system (TissueFAXS™, TissueGnostics GmbH).

The ratio of epithelial versus stromal area was assessed in 8 samples from colorectal cancer patients.

Four patients were diagnosed with liver metastases at the time of operation. In control experiments, normal mucosa regions from healthy patients (2) were also analyzed.

References:

- Mesker et al., Cell Oncol. 2007;29(5):387-98.
- Kruijff et al., Breast Cancer Res Treat. 2011; 125(3):687-96.

Acknowledgements

This project is funded by FFG (Bridge 818094).